

Perio meets implant dentistry

A time-tested relationship

Author_Rainer Buchmann, Düsseldorf

_Introduction

The preservation of the natural dentition is the prerequisite in daily patient care. In advanced periodontal disease, the successful realization of implant therapy requires knowledge in patient expectations, clinical diagnostics, proper surgical skills and delegation of basic services to dental hygienists. Implant treatment in severe periodontitis demands a two-step, time-tested approach, evaluating the outcomes of basic periodontal therapy before implant placement.

_Integrated dentistry: Success for today and tomorrow

The successful positioning of dental partnerships in the fast-growing health market implicates predictable treatment strategies to save permanent teeth. According to orthopedic, cardiac or vascular medicine, an on-time decision-making for implant therapy is recommended to counterbalance functional and esthetic discomfort in advanced endodontic and periodontal breakdown settings. Patient's current and future expectations drive our practices into the necessity to provide synergistic periodontal and implant treatment solutions. The advantages are:

- Optimizing implant success by preceding with periodontal therapy.
- Enhanced economic profit due to by-effects from delegated scaling and root planing.
- Promotion of oral and body health of both dental patients and staff members.

The need to preserve healthy teeth and gums, the ever-expanding influences of web, TV and magazines and an increase in low-cost implant treatment render implant dentistry internationally attractive. The transition of dental practices into the implant market is reasonable, especially for growing dental partnerships. The capital investment and running costs for a surgical im-

plant setting are redeemed by more than 30 implants a year. Because of the economic commitment, a careful financial strategy is needed not to neglect challenges and developing concepts preserving and salvaging compromised teeth from conservative and periodontal dentistry.

_Decision-making in periodontal diseases

Classical implant therapy protocols comprise must-indications resulting in an immediate treatment plan. According to patient preferences, clinical settings and insurance plans, these must-indications with an adhoc implant placement recommendation are, in order of precedence:

- Long-term missing bridgeworks or prosthesis, edentulous mandible
- Advanced endodontic damage
- Trauma (tooth fracture)
- Oral cancer surgery

Periodontal diseases represent can-indications. Treatment planning is running more complex. The decision-making comprises a time-tested therapeutic approach. In advanced periodontal settings of more than 50 % bone loss with furcation involvement level III, patients suffer from oral discomfort. The tooth prognosis

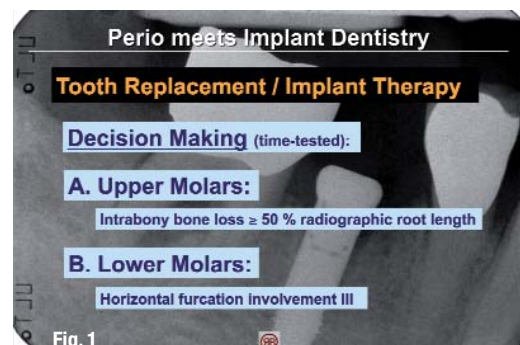


Fig. 1 Treatment of advanced periodontal disease with implants replacing the natural dentition is recommended "time-tested" 3 to 6 months following periodontal therapy (SRP).

becomes less positive, the frequencies of follow-up visits increase (Fig. 1). Periodontal therapy "before" implant planning is aimed at saving doubtful (not hopeless) teeth with a grace period of at least three to six months to evaluate for periodontal treatment outcomes. Thorough scaling and root planing frequently results in a mid-term improvement (two years) up to a long-term stabilization (five years) of preliminary affected teeth.

The decision to maintain the periodontally compromised dentition undergoes the following criteria (Fig. 2):

- Patients with no personal preferences to comfort, esthetics and costs
- Patients willing to accept enhanced tooth mobility, occasional food impaction and frequent professional tooth cleaning
- Individuals with chronic diseases and autoimmune disorders

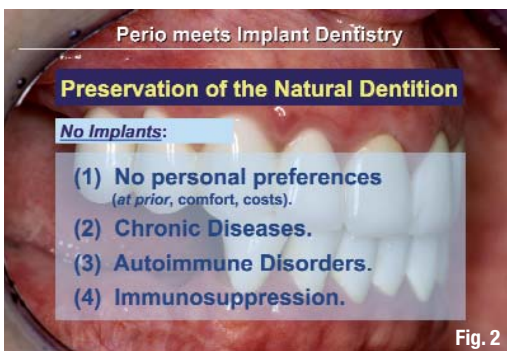

Fig. 2

The recommendation to replace affected teeth with implants is indicated in the following clinical situations and should be planned on-time after completion of periodontal therapy (three to six months):

- Patients running a demanding business striving for fixed teeth
- Enhanced masticatory and cleaning comfort
- Long-term rehabilitation with low input in time, effort and expenses.

Currently, the items above are effective at implant placements within the local bone, minor lateral hard and soft tissue deficiencies, following sinus floor elevation, in settings with sufficient implant abutment distances of 3 mm and after periodontal therapy. Extended surgical protocols enhance treatment time (Fig. 3), ren-

Implant Treatment Protocol		
1. Visit:	Basic Implant Exam	(1/2 h)
	X-Ray, Alveolar bone width, Charges, DVT (Reduced bone support)	
2. Visit:	Removal Bridgework	(1 h)
3. Visit:	a. Implant Surgery*	(1 h)
	+ Sinus Elevation	(+1 h)
	+ Augmentation (lat./vert.)	(+1 h)
	b. Periodontal Regeneration	(1/2 h)
4. Visit:	1. Visit post-OP	(2 weeks) (1/4 h)
		(Bill Surgery)
5. Visit:	Fixed / Removal Prostheses	
	* Front or molars / jaw (Mandible 4, Maxilla 6 mm.)	

Fig. 3

der the case prognosis uncertain and may aggravate long-term success.

Implant therapy in advanced periodontal disease

The survival rates of teeth with severe periodontal damage published in evidence-based studies are rarely valid for patients inquiring treatment in dental offices (Fig. 4). Shortcomings in oral hygiene, lack in supportive care, oral dysfunctions, stress, smoking and general disorders abbreviate the function times of periodontally-compromised teeth sustainably.

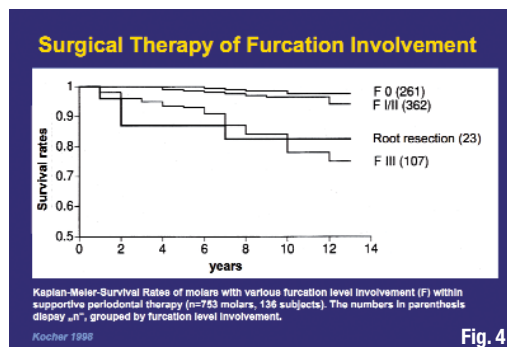


Fig. 4

The advice to replace affected teeth with implants in advanced periodontal settings within the maxilla implicates on-time patient information of the second and third molar removal: implant placement and prosthetic bridge works are scheduled in the functional masticatory area until to the first molar. In the mandible, the second molars can be preserved due to their beneficial root anatomy. They should be restored, but not included in implant planning. Following the removal of the first molar in the maxilla, implant therapy is often preceded (if the supporting bone is less than 4 mm) or accompanied by a simultaneous sinus lift. The implant treatment plan in periodontally compromised patients results in a reduced dentition (Fig. 5):

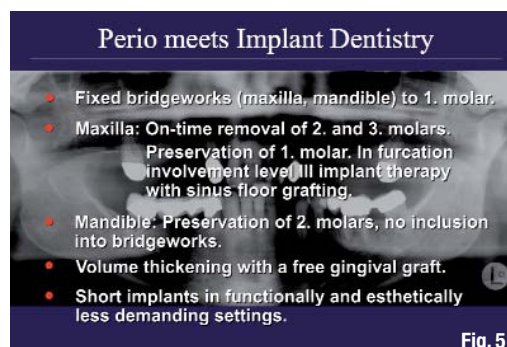


Fig. 5

- Fixed bridgeworks in the maxilla and mandible up to the first molar
- Maxilla: preservation of premolars and first molars, tooth removal and implant therapy with sinus floor elevation at furcation involvement level III (Fig. 6)
- Mandible: preservation of second molars, restoration, no inclusion into bridgeworks

Fig. 2 Exclusion criteria for implants with continuation of saving natural teeth after comprehensive periodontal therapy.

Fig. 3 Implant therapy should be performed with minimal augmentation. Extended surgical therapy prolongs treatment time, renders case prognosis unsafe and may aggravate long-term success.

Fig. 4 Unexpected life-events half cut the survival rates of teeth with advanced periodontal bone loss in daily practice down to 5-7 years.

Fig. 5 Guidelines to a safe implant treatment protocol in advanced periodontal disease.

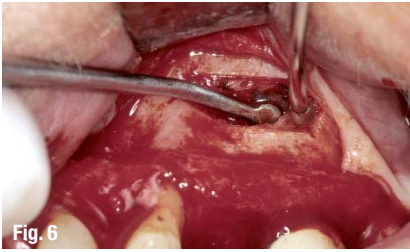


Fig. 6

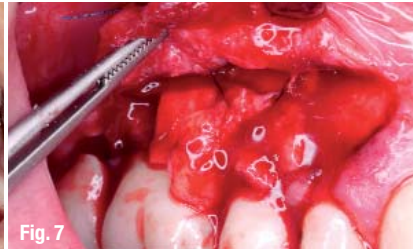


Fig. 7



Fig. 8

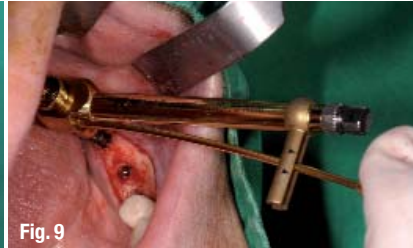

Fig. 9

Fig. 6 The piezosurgical access to the lateral sinus is the best approach to promote implant supported bone in the maxilla. Short implants are not advocated, internal lifts technique-sensitive.

Fig. 7 Volume thickening with a free gingival graft in an initial thin tissue with buccal perforation.

Fig. 8 Short implants are advised in critical anatomic situations when the alveolar bone width is sufficient. Functionally, they represent no alternative to classical augmentation protocols. (Photo: Kochhan)

Fig. 9 Insertion of short implants close to the alveolar nerve in the mandible with sufficient alveolar bone width. (Photo: Kochhan)

Fig. 10 Implants require a comprehensive maintenance care. Periimplant inflammations display foreign body infections that are more harmful for the body health than periodontal diseases.

Fig. 11 Periodontal therapy lowers the inflammatory burden and promotes health while optimizing body metabolism with stimulating effects onto the vascular system.

– Volume thickening with free autogenous gingival grafts in initial thin biotype settings (Fig. 7)
 – Short implants in both esthetically and functionally less demanding situations as an alternative to surgical augmentation (Fig. 8).

Low bone quality (D3/D4), lateral hard-tissue deficiencies and increased mechanical loading are contraindications for short implants. According to conventional implant rehabilitation, the horizontal width of the alveolar bone crest is the fundament for functional stabilization, vascularization and nutrition, thus for implant survival and clinical success (Fig. 9).

Inflammation and hygiene

Clinical healthy and stable implants are completely covered within the alveolar bone by osseointegration. They also are attached to the periimplant gingiva and thereby become functionally included into the body's metabolism. This explains the high overall survival rates of oral implants between eight and more than 15 years. The combination of

- a thin biotype gingiva with lack of soft tissue protection
- functional overload due to stress, habits or a missing front-canine equilibration, and
- loss of biofilm protection by periodontal diseases

often causes mid-term damages (two years after functional loading) of the implant-to-bone interface. Like periodontally affected teeth with lack of hygiene access and enhanced biofilm accumulation, implants develop a potential risk of inflammation when bacteria enter the implant-to-bone interface (Fig. 10). If the close hard and soft tissue sealing disappears irreversibly, foreign-body infections occur within the oral cavity which are more harmful for the implant-supporting bone and the body health than periodontal diseases. The best protection against periimplant inflammation is not avoiding implants: a careful implant placement strategy with con-

comitant thickening of the surrounding tissues and relief from functional overload preceded by comprehensive periodontal therapy (hygiene) are the best therapeutic helpers for implant survival and oral health (Fig. 11).

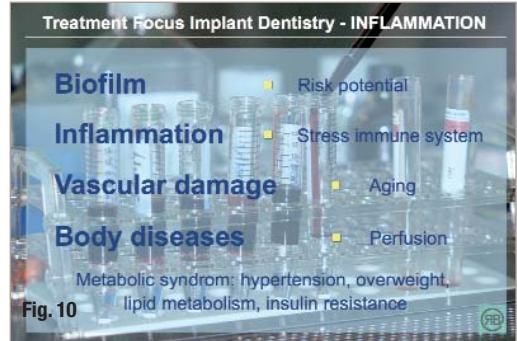


Fig. 10

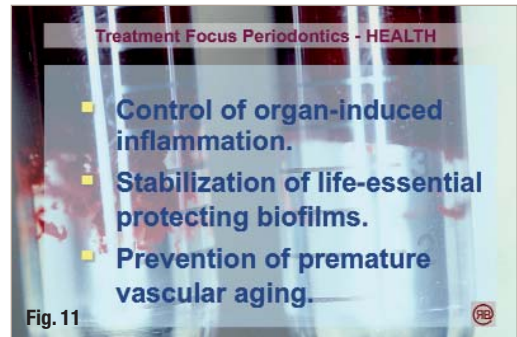

Fig. 11

Summary

In advanced periodontal diseases, the network between medical progress and ever-expanding patient's expectations requires a time-tested schedule with a grace period of three to six months to evaluate the affected dentition for periodontal treatment outcomes. If patients anticipate immediately fixed and esthetic restorations, on-time implant therapy with minimal augmentative solutions is recommended. Preservation of periodontally compromised natural teeth is advised when patients display no preference for further comfort and esthetics. Periodontal therapy is continued, supplemented with surgery in advanced intrabony settings where oral hygiene is impaired. The long-term success for the natural dentition and implants similarly depends on patient's medical and local risk factors that cannot be forecasted with any genetic or susceptibility test for sale.

<u>contact</u>	implants
<p>Prof Dr Rainer Buchmann Practice limited to Periodontics Königsallee 12, 40212 Düsseldorf, Germany Tel.: +49 211 8629120</p> <p>E-Mail: info@rainer-buchmann.de www.rainer-buchmann.com</p>	